

Left Heel Decubitus Wound with Exposed Bone

Case performed by: *Kenny Luong, DPM, FACFAS*

CASE STUDY

Patient & Diagnosis:

- 60-year-old male with diabetes mellitus and end-stage renal disease on hemodialysis
- Left heel decubitus wound with exposed bone

Previous Treatment:

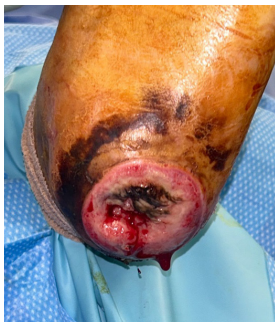- Standard of care/local wound care

Wound Treatment:

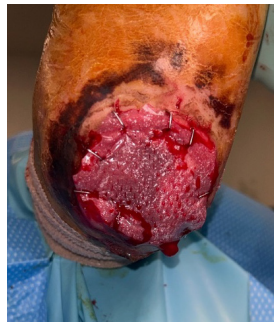- OR debridement
- TheraGenesis and wound vac application
- Dermacell AWM application
- TheraSkin application

Outcome:

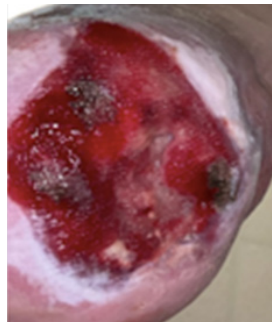
- Wound closure in 17 weeks



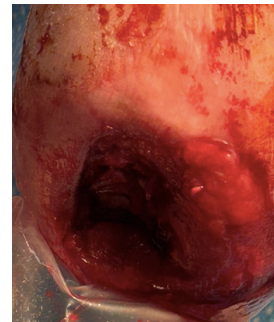Initial Wound:
After standard of care, pre OR debridement



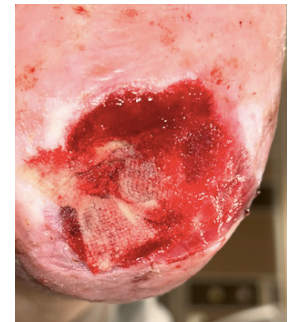TheraGenesis Application 1



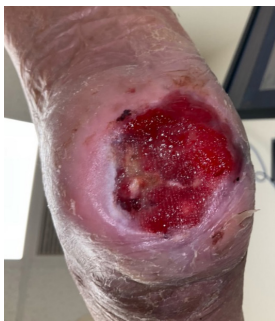Week 3



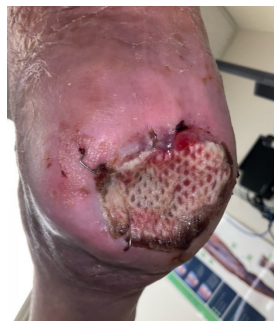Week 4:
Dermacell AWM application



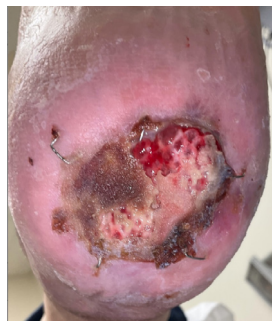
Week 5:
One week post Dermacell AWM application



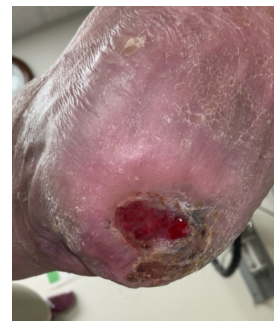Week 8:
Three weeks post Dermacell AWM; application of TheraSkin in the outpatient setting



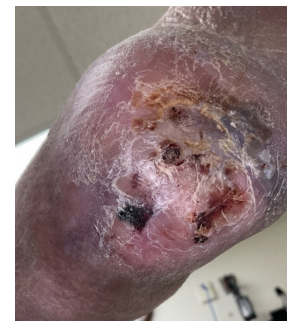Week 9:
One week post TheraSkin application



Week 10:
Two weeks post TheraSkin application



Week 13



Week 17