

# TheraSKIN<sup>®</sup>: Venous Leg Ulcer Wound

## CASE STUDY

### Patient & Diagnosis:

- 56-year-old male
- Congestive heart failure with eschar

### Previous Treatment:

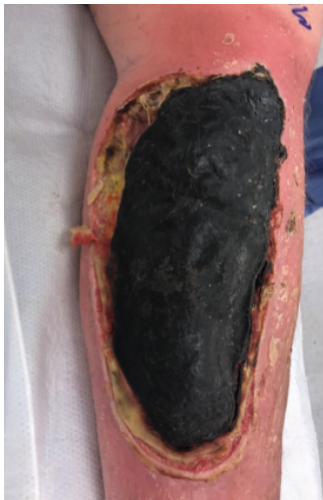- None

### Wound Treatment:

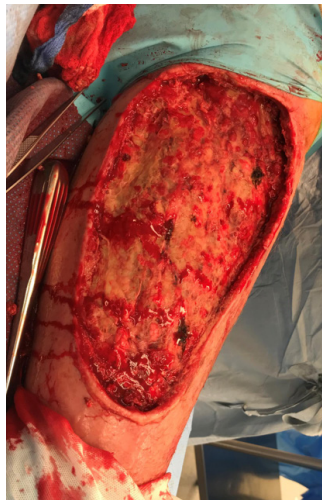
- Two TheraSkin applications

### Outcome:

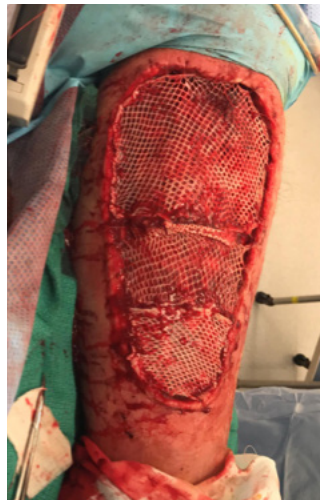- Wound closed in 19 weeks



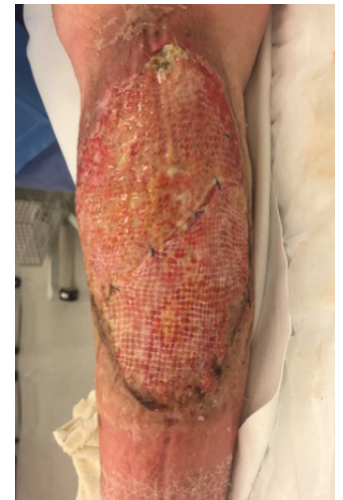Initial Wound



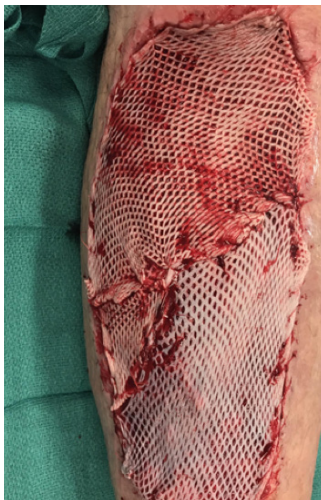
Initial Wound:  
After debridement



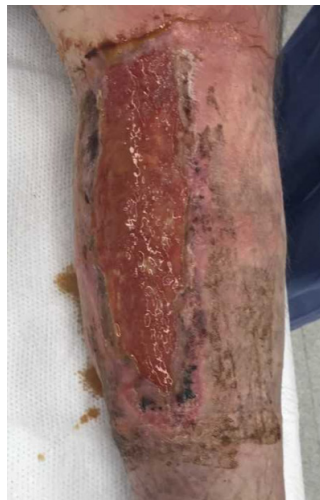First Application:  
First TheraSkin application



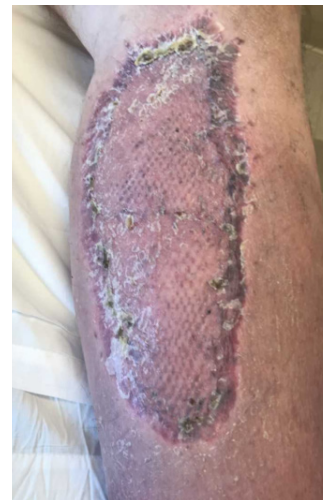Week 1:  
Dressing change



Week 3:  
Second TheraSkin application



Week 9:  
Wound ready for STSG



Closure:  
19 weeks, wound healed