

MATRACELL®-Processed Dermis Augments Finger Extensor Tendon Reconstruction

Andrea Atzei MD¹, Giampietro Bertasi MD, PhD²

¹University of Verona, Orthopedic Department, ²University of Padua

CASE STUDY

Matracell®-processed dermis from LifeNet Health is a human acellular dermal matrix (ADM) that can be used for the repair, reconstruction, augmentation, and reinforcement of soft tissues such as tendons and ligaments.¹⁻⁴ The bio-implant is processed using proprietary technologies which make it resistant to premature enzyme degradation, biocompatible, and safe.⁵ This bio-implant is an effective scaffold that has demonstrated recellularization and revascularization properties in vivo.⁶

The patient was a 40-year-old male with a complete deficit of active extension of the middle finger proximal interphalangeal after an open crushing injury over the dorsal aspect of the middle finger of his left, non-dominant hand during a car accident three years earlier. Dorsal skin, the extensor apparatus at both the proximal and middle phalanges, and the proximal interphalangeal joint (PIP-j) were injured.

The patient presented eight months after the injury with a large attenuated scar over the dorsal aspect of the finger that maintained the PIP-j in full extension following total joint replacement. After resection of the lengthened scar tissue, Matracell-processed dermis was used to augment the direct repair of the central tendon.

The following case presentation involves treatment of a ruptured distal triceps tendon with this human decellularized dermis

Patient

- 40 year-old male
- Sustained an open crushing injury over the dorsal aspect of the middle finger of his left, non-dominant hand during a car accident. The dorsal skin, the extensor apparatus at both the proximal and middle phalanges, and the proximal interphalangeal joint (PIP-j) were injured.
- The patient presented eight months after the injury with a large attenuated scar over the dorsal aspect of the finger that maintained the PIP-j in full extension.
- Total PIP-j replacement was performed with a Pyrocarbon implant, resulting in severe extension lag (Fig. 1) and an extensor tendon reconstruction was performed six months later (Fig. 2).

Treatment

- Tendon repair was performed by an Ethibond 2-0 core suture, reinforced with a Prolene 4-0 running stitch (Fig. 3). Due to the poor quality of the tendon, the repair site was augmented with a strip of Matracell-processed dermis overlaid over the repair site and secured with Prolene 4-0 interrupted sutures (Fig. 4).

- The tourniquet was deflated after the repair and the patient was asked to actively move the finger intraoperatively (Fig. 5). Full PIP-j extension was achieved as well as 90° flexion without any detectable damage to the repair site. The wound was then irrigated and the skin closed with interrupted sutures.
- The finger was splinted in slight flexion for two weeks and an early rehabilitation program started. A progressive increase to maximal flexion was allowed over the following four weeks.

Conclusion

- Excellent augmentation of the extensor apparatus at the PIP-j was achieved
- Post-operative course was uneventful: no swelling was observed that would alter the finger shape
- Observed Matracell-processed dermis did not adhere to skin in this case
- Three month post-operative, the patient regained 10° to 90° ROM (Fig. 6)
- Augmentation with Matracell-processed dermis proved to be an effective option for extensor tendon reconstruction

MATRACELL®-Processed Dermis Augments Finger Extensor Tendon Reconstruction

CASE STUDY

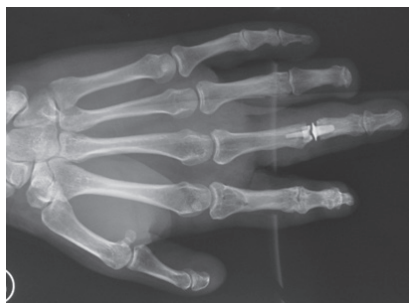

Figure 1. Pre-operative X-ray showing AP

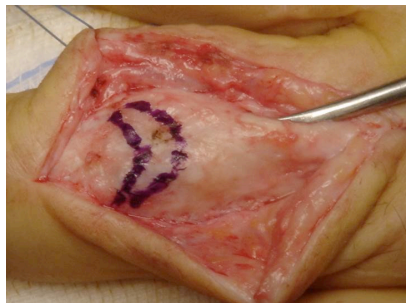


Figure 2. Pre-operative image of the central tendon

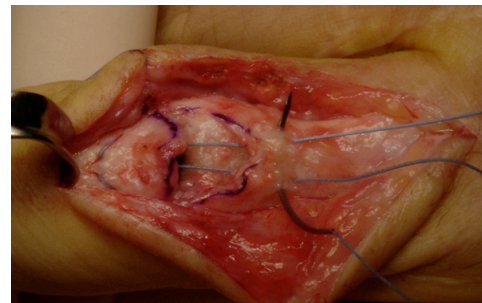


Figure 3. Tendon repair suture reinforced with running stitch

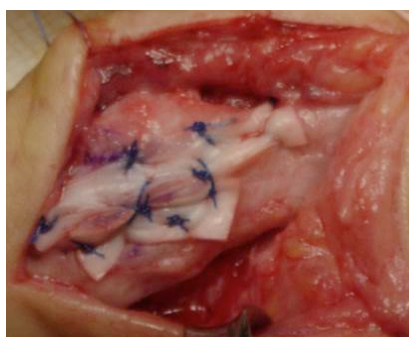


Figure 4. Augmentation with Matracell-processed dermis

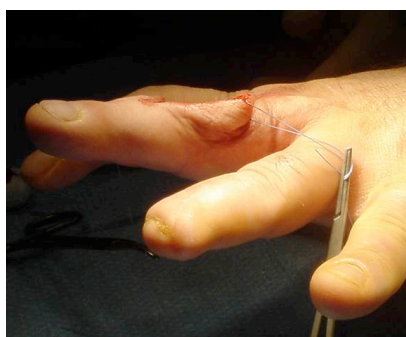


Figure 5. Intraoperative check

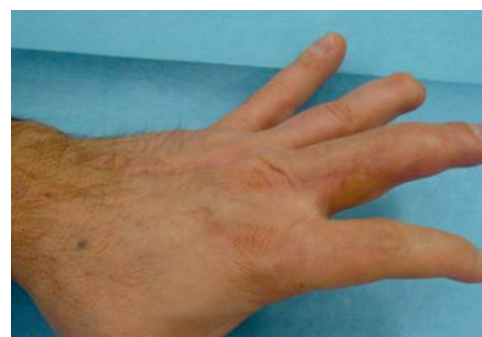

Figure 6. Three months post-operative, patient regained 10° to 90° ROM

References

1. Levenda AC, Sanders N. A simplified approach for arthroscopic repair of rotator cuff tear with dermal patch augmentation. *Advances in Orthopedic Surgery* 2015;2015:423949.
2. Gilot GJ, Alvarez AM, Barcksdale L, et al. Outcome of large to massive rotator cuff tears with and without extracellular matrix augmentation: a prospective comparative study. *Arthroscopy* 2015;31:1459-1465.
3. Gilot GJ, Attia AK, Alvarez AM. Arthroscopic repair of rotator cuff tears using extra-cellular matrix (ECM) graft. *Arthrosc Tech* 2014;3:e487-e489.
4. Lee B, Acevedo D, Mirzayan R. Reconstruction of the acromioclavicular joint, its superior capsule, and coracoclavicular ligaments using an interpositional acellular dermal matrix and tibialis tendon allograft. *2014 Tech Should Surg*; 15:79-86.
5. Moore MA, Samsell B, Wallis G, et al. Decellularization of human dermis using non-denaturing anionic detergent and endonuclease: a review. *Cell Tissue Bank* 2015;16:249-259.
6. Capito A, Tholpady S, Agrawal H, et al. Evaluation of host tissue integration, revascularization, and cellular infiltration within various dermal substrates. *Ann Plast Surg* 2012;68:495-500.

LifeNet Health helps to save lives, restore health and give hope to thousands of patients each year. We are the world's most trusted provider of transplant solutions, from organ procurement to new innovations in bio-implant technologies and cellular therapies—a leader in the field of regenerative medicine, while always honoring the donors and healthcare professionals who allow the healing process.

LifeNetHealth.org

The LifeNet Health logo and Matracell are registered trademarks of LifeNet Health. ©2019 LifeNet Health, Virginia Beach, VA. All rights reserved. 68-20-159.01