

Vestibuloplasty Using OrACELL[®], a Human Acellular Dermal Matrix (ADM)

Dr. Kuan-Chou Lin, Taipei Medical University - Municipal Wan Fang Hospital, Oral-Maxillofacial Surgery Department

CASE STUDY

A vestibuloplasty procedure is used to correct issues involving instability and retention of denture wear caused by insufficient depth of the vestibule.^{1,2,3} Several techniques exist to deepen the vestibule including sub-mucosal vestibuloplasty,⁴ secondary epithelialization vestibuloplasty,⁵ and soft tissue grafting vestibuloplasty.^{3,6,7} In the past, autografts taken from the palatal mucosa were used in vestibuloplasty procedures; however, increased morbidity, bleeding, and other surgical risks typically occur with autograft use.^{2,3,8} For these reasons, acellular dermal matrix allografts are used to avoid these issues.

An alternative method of treatment used in vestibuloplasty procedures involves the use of an Acellular Dermal Matrix (ADM), which has demonstrated application in a variety of medical procedures, including wound healing, soft tissue reconstruction, and sports medicine applications.⁹⁻¹² These dermal matrices have been demonstrated to support cellular and vascular in-growth *in vitro* and *in vivo*.¹³⁻¹⁵ One particular human allograft ADM, Oracell, is uniquely prepared resulting in at least 97% DNA removal and provided sterile at room temperature, ready to use.

The following case presentation involves a vestibuloplasty performed using this novel human ADM, Oracell.

Patient

- 51-year-old, Female

Diagnosis

- Patient had insufficient vestibule depth (4 mm) (Figure 1)
- Vestibuloplasty necessary to treat with implants
- Preoperative alveolar ridge height of 8-10 mm
- Patient was not edentulous

Treatment

- One (1) 1.5 cm x 2 cm piece of Oracell ADM was applied (Figure 2)
- Post-operatively the width of fixed tissue was 6 mm

Outcome

- Wound had completely healed by 8 weeks post-op (Figure 3)
- Use of Oracell ADM was successful

Vestibuloplasty Using OrACELL[®], a Human Acellular Dermal Matrix (ADM)

CASE STUDY

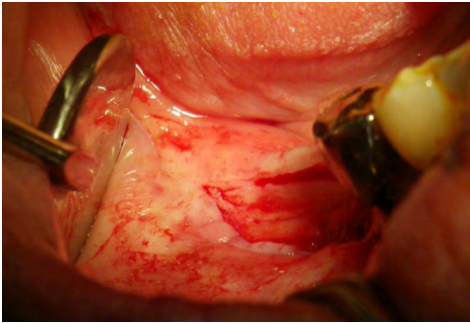

Figure 1.
Pre-operative image showing lack of vestibule depth

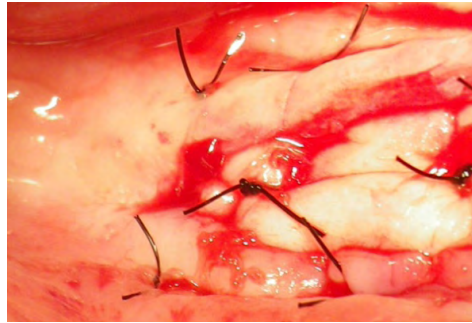


Figure 2.
Surgical placement of Oracell for vestibule extension

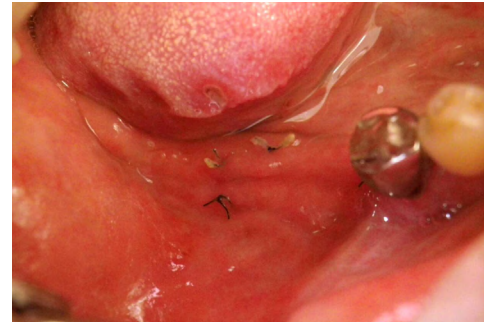

Figure 3.
Post-operative healing and integration of Oracell at wound site by 8 weeks post-operatively

Results from case studies are not predictive of results in other cases. Results in other cases may vary.

References

1. Gregory EW, Triplett RG, Connole PW. Comparison of fresh autogenous and freeze-dried allogenic skin for mandibular vestibuloplasty. *J Oral Maxillofac Surg.* 1983; 41:75-79
2. Hashemi HM, Parhiz A, Ghafari S. Vestibuloplasty: allograft versus mucosal graft. *Int J Oral Maxillofac Surg.* 2012; 41:527-30
3. Bholra M, Newell DH, Hancock EB. Acellular dermal allograft for vestibuloplasty – an alternative to autogenous soft tissue grafts in preprosthetic surgical procedures: a clinical report. *J Prosthodontics.* 2003; 12(2):133-37
4. Obwegeser H. Surgical preparation of the maxilla for prosthesis. *J Oral Surg.* 1964; 22:127-34
5. Kazanjian VH. Surgery as an aid to more efficient service with prosthetic dentures. *J Am Dent Assoc.* 1935; 22:566-72
6. Hall HD, O'Steen AN. Free grafts of palatal mucosa in mandibular vestibuloplasty. *J Oral Surg.* 1970; 28:565-82
7. Froschl T, Kerscher A. The optimal vestibuloplasty in pre-prosthetic surgery of the mandible. *J Craniomaxillofac Surg.* 1997; 25(2):85-90
8. Raguse JD, Gath HJ. A metabolically active dermal replacement (Dermagraft) for vestibuloplasty. *J Oral Rehabil.* 2005; 32:337-40
9. Wong I, Burns J, Snyder S. Arthroscopic graftjacket repair of rotator cuff tears. *J Shoulder Elbow Surg.* 2010; 19(2):104-109
10. Wilkins, R. Acellular dermal graft augmentation in quadriceps tendon rupture repair. *Curr Orthop Pract.* 2010; 21(3):315-19
11. Lee, Daniel. Achilles tendon repair with acellular tissue graft augmentation in neglected ruptures. *J Foot Ankle Surg.* 2007; 46(6): 451-55
12. Sbitany H, Sandeen S, Amalfi A, et al. Acellular dermis-assisted prosthetic breast reconstruction versus complete submuscular coverage: a head-to-head comparison of outcomes. *Plast Reconstr Surg.* 2009; 124:1735-40
13. Wainwright DJ, Bury SB. Acellular dermal matrix in the management of the burn patient. *Aesthet Surg J.* 2011; 31(7):135-235
14. Capito AR, Tholpady SS, Agrawal H, Drake DB, Katz AJ. Evaluation of host tissue integration, revascularization, and cellular infiltration within various dermal substrates. *Ann Plast Surg.* 2012;68:495-500.
15. Armour AD, Fish JS, Woodhouse KA, Semple JL. A comparison of human and porcine acellularized dermis: Interactions with human fibroblasts in vitro. *Plast Reconstr Surg.* 2006;117(3):845-56.

LifeNet Health helps to save lives, restore health and give hope to thousands of patients each year. We are the world's most trusted provider of transplant solutions, from organ procurement to new innovations in bio-implant technologies and cellular therapies—a leader in the field of regenerative medicine, while always honoring the donors and healthcare professionals that allow the healing process.

LifeNetHealth.org

LifeNet Health, the LifeNet Health logo, and Oracell are registered trademarks of LifeNet Health.

©2021 LifeNet Health, Virginia Beach, VA. All rights reserved.

68-20-100.01