

# Treatment of Severe Mandibular Hypoplasia using Vivigen Formable® Cellular Bone Matrix combined with Custom Intraoral Guides and Plates in Two Patients

Case performed by: David Alfi, MD, DDS, Kevin Coppelson MD, DDS, Jennifer P. Caroline MD, DDS, Michael F. Huang, MD, DDS, Houston, TX, USA

CASE STUDY

Mandibular hypoplasia is a common skeletofacial deficiency associated with a decreased size and/or projection of the mandible, which can be challenging to treat.<sup>1</sup> Bimaxillary surgery is commonly employed to achieve the desired functional and aesthetic outcomes. This approach requires precise three-dimensional repositioning of both the maxilla and mandible often without adequate biologic landmarks intraoperatively. Additionally, large interpositional gaps are often created, which, if left untreated, may lead to pseudarthrosis, instability, and potential relapse.<sup>2,3</sup> One bone grafting option is autograft bone. Autograft bone can provide the osteoconductive, osteoinductive, and osteogenic properties needed for successful bone fusion; however, the retrieval of the autograft can cause pain and donor-site morbidity to patients.<sup>4</sup>

An allograft alternative, Vivigen<sup>®</sup>, also provides all three of these properties while avoiding donor-site morbidity. Vivigen is processed from donated human tissue and is intended for repair, replacement, or reconstruction of musculoskeletal defects. Vivigen is an osteoconductive scaffold that contains viable cells committed to produce bone in concert with osteoinductive signals naturally found in demineralized bone. Preclinical studies suggest bone cells might improve fusion over mesenchymal stem cells by providing better bone deposition<sup>5</sup> while remaining in the defect site longer.<sup>6</sup>

The following describes the use of Vivigen Formable combined with custom intraoral guides and plates to treat two patients with severe mandibular hypoplasia, one of whom is pediatric.

## Patient #1

- 58-year-old female
- Presented with significant Class II malocclusion (Figure 1A, B)
- Cone-beam computed tomography (CBCT) scans revealed jaw deformity, including asymmetry and mandibular hypoplasia with a V-shaped mandible, and a small posterior airway space (Figure 2A, B).

## Procedure

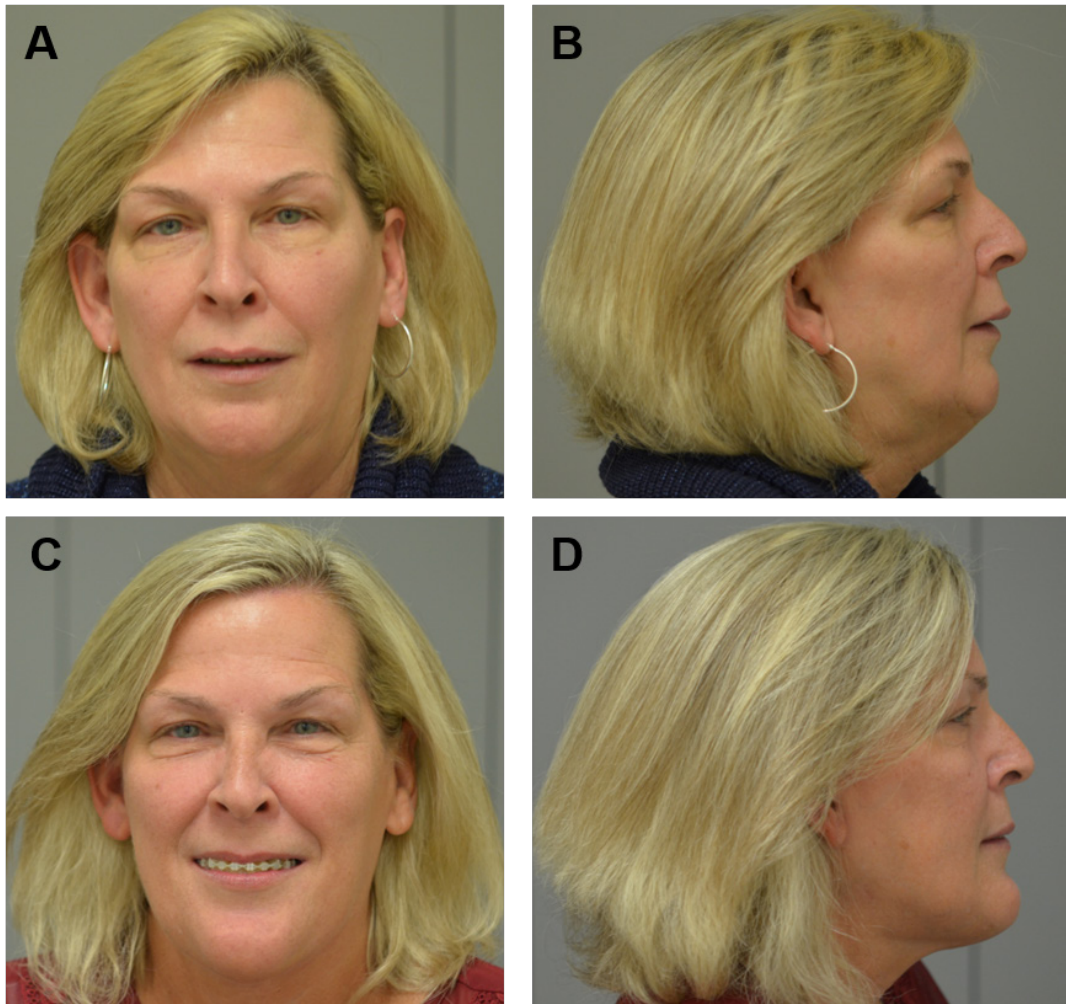- A presurgical plan was developed using TRUMATCH<sup>®</sup> CMF Personalized Solutions (DePuy Synthes) based on the preoperative CBCT images to create custom-fabricated guides and plates for each surgical procedure (Figure 2C, D).
- The patient underwent bimaxillary surgery, including a LeFort I Osteotomy, bilateral inverted-L osteotomy, and genioplasty, via an intraoral approach. Ten cc Vivigen Formable was used to fill the interpositional gaps created in each procedure.
- Total operative time was 6 hrs 47 min.

## Results

- At 4 months postoperative, the patient reported doing well, with no complications, and was extremely satisfied with the outcome (Figure 1C, D). The planned maxillary and mandibular positional changes were successfully achieved, with an anterior movement of pogonion of 25 mm, indicating restoration of normal occlusion.
- At 6 months postoperative, CBCT and radiographic scans revealed excellent healing and integration of Vivigen Formable with evidence of osseous consolidation at the osteotomy sites (Figure 3).

# Treatment of Severe Mandibular Hypoplasia using ViviGen Formable® Cellular Bone Matrix combined with Custom Intraoral Guides and Plates in Two Patients

CASE STUDY

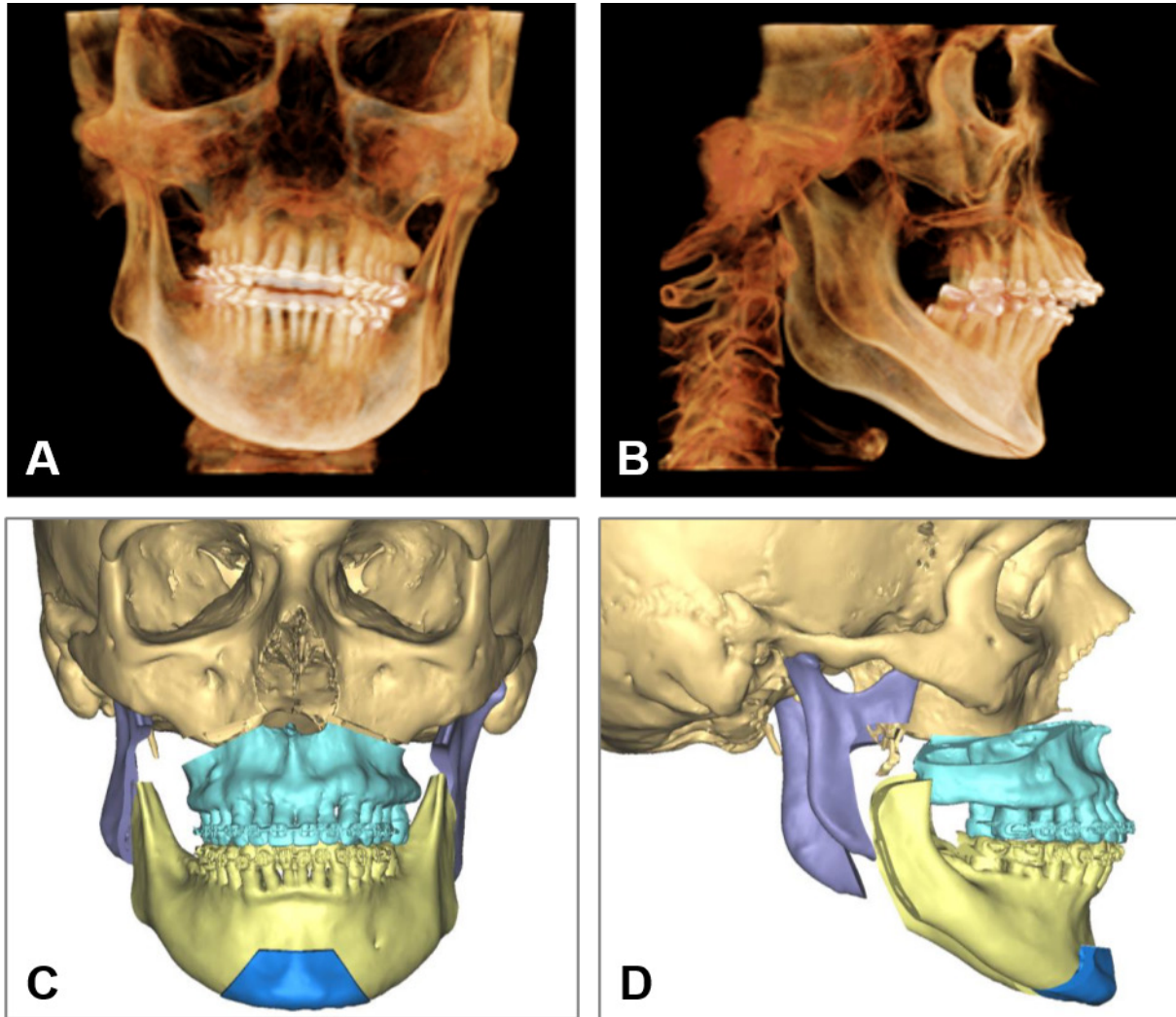


**Figure 1.**

Preoperative anterior (A) and lateral (B) photographs of patient 1 revealed characteristics of mandibular hypoplasia and significant Class II malocclusion. Anterior (C) and lateral (D) postoperative photographs taken at 4 months demonstrate normal occlusion was restored. The patient was extremely satisfied with the outcomes.

# Treatment of Severe Mandibular Hypoplasia using ViviGen Formable® Cellular Bone Matrix combined with Custom Intraoral Guides and Plates in Two Patients

CASE STUDY

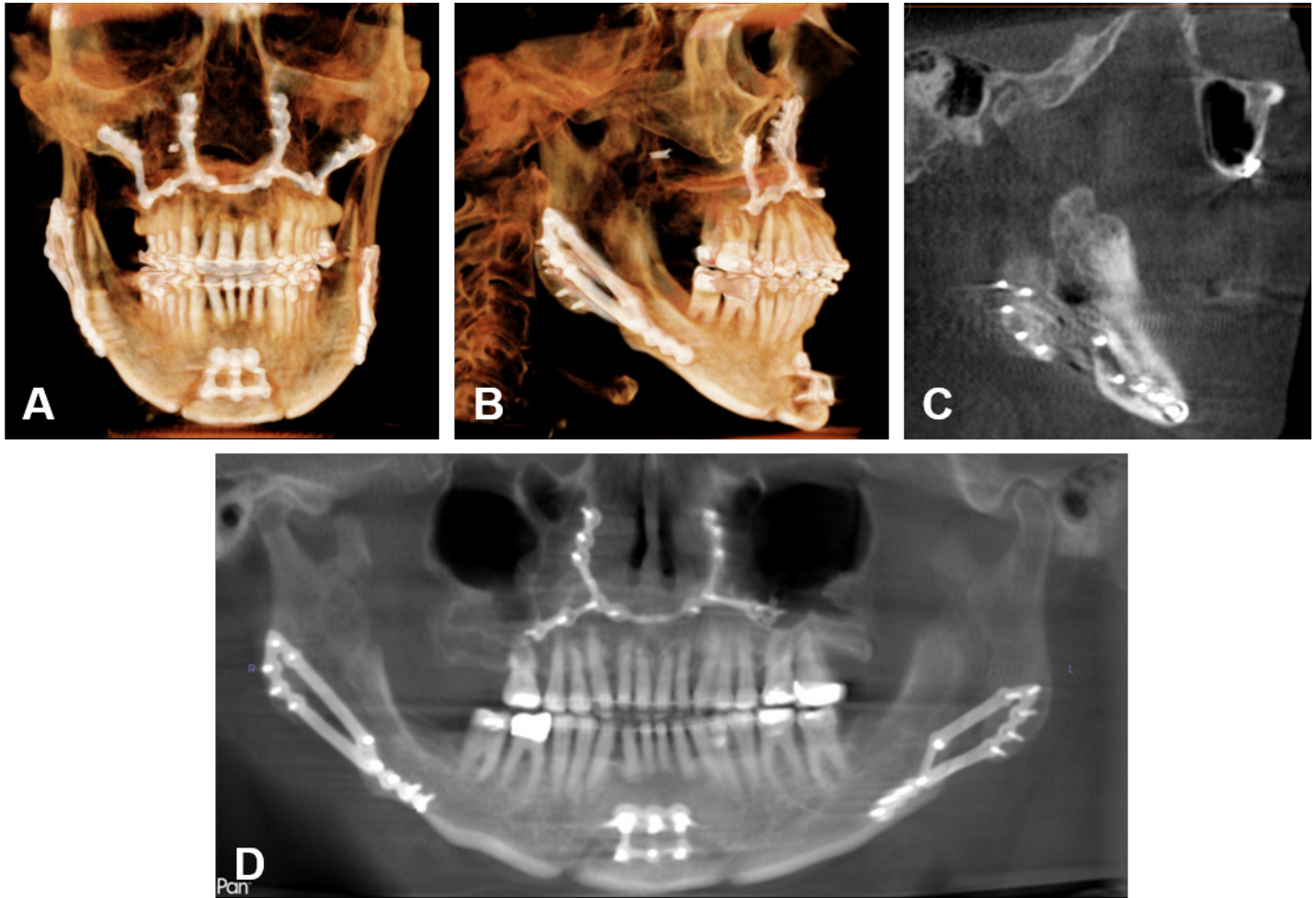


**Figure 2.**

Cone-beam computed tomography (CBCT) images of patient 1 showing the anterior (A) and lateral (B) views demonstrate facial asymmetry, mandibular hypoplasia, and a small posterior airway space. Three-dimensional reconstructed CBCT images from the presurgical plan showing the planned positional changes of the maxilla and mandible (C and D). The presurgical plan indicated an advancement of 7 mm and 16 mm for the maxilla and mandible, respectively.

# Treatment of Severe Mandibular Hypoplasia using ViviGen Formable® Cellular Bone Matrix combined with Custom Intraoral Guides and Plates in Two Patients

CASE STUDY



**Figure 3.**

Postoperative clinical images of patient 1 taken at 6 months. Anterior and posterior CBCT (A and B, respectively) images, sagittal CBCT section (C), and a reconstructed panoramic radiograph (D) demonstrate excellent integration of ViviGen Formable and progressed osseous healing at the osteotomy sites.

# Treatment of Severe Mandibular Hypoplasia using ViviGen Formable® Cellular Bone Matrix combined with Custom Intraoral Guides and Plates in Two Patients

## CASE STUDY

### Patient #2

- 15-year-old female
- Presented with significant Class II malocclusion that started 4 years prior, severe deformity of her lower jaw (Figure 4A), and complaints of difficulty speaking and chewing.
- CBCT scans confirmed significant mandibular hypoplasia and a small posterior airway space (Figure 5A, B).

Formable was used to fill the interpositional gaps created in each procedure.

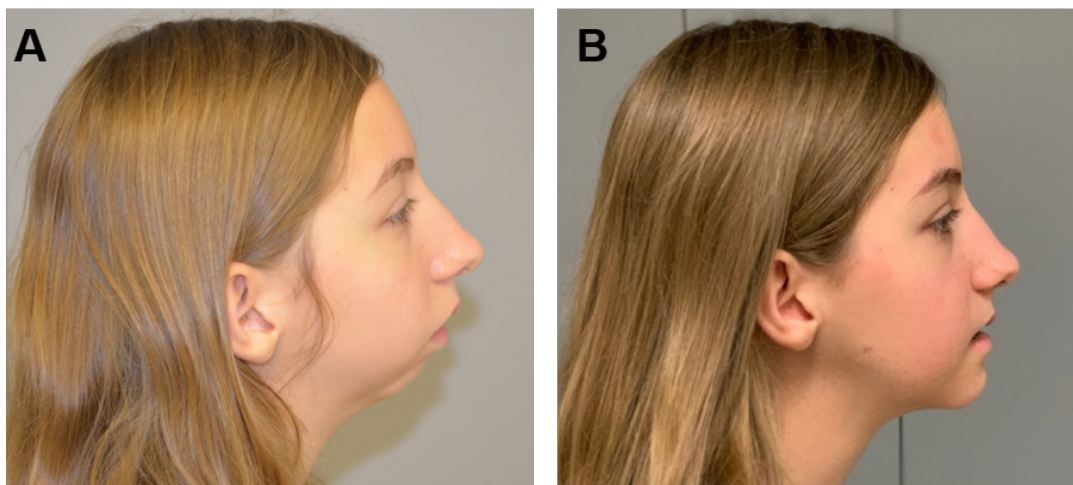
- Total operative time was 5 hrs 59 min.

### Results

- At 2 months postoperative, the patient reported doing well, with no complications, and was extremely satisfied with the outcome (Figure 4B). The planned maxillary and mandibular positional changes were successfully achieved, with an anterior movement of pogonion of 42mm, indicating restoration of normal occlusion.
- At 6 months postoperative, CBCT and radiographic scans revealed excellent healing and integration of ViviGen Formable with evidence of osseous consolidation at the osteotomy (Figure 6).

### Procedure

- A presurgical plan was developed using TRUMATCH® CMF Personalized Solutions (DePuy Synthes) based on the preoperative CBCT images to create custom-fabricated guides and plates for each surgical procedure (Figure 5C, D).
- The patient underwent bimaxillary surgery, including a LeFort I Osteotomy, bilateral inverted-L osteotomy, and genioplasty, via an intraoral approach. Ten cc ViviGen

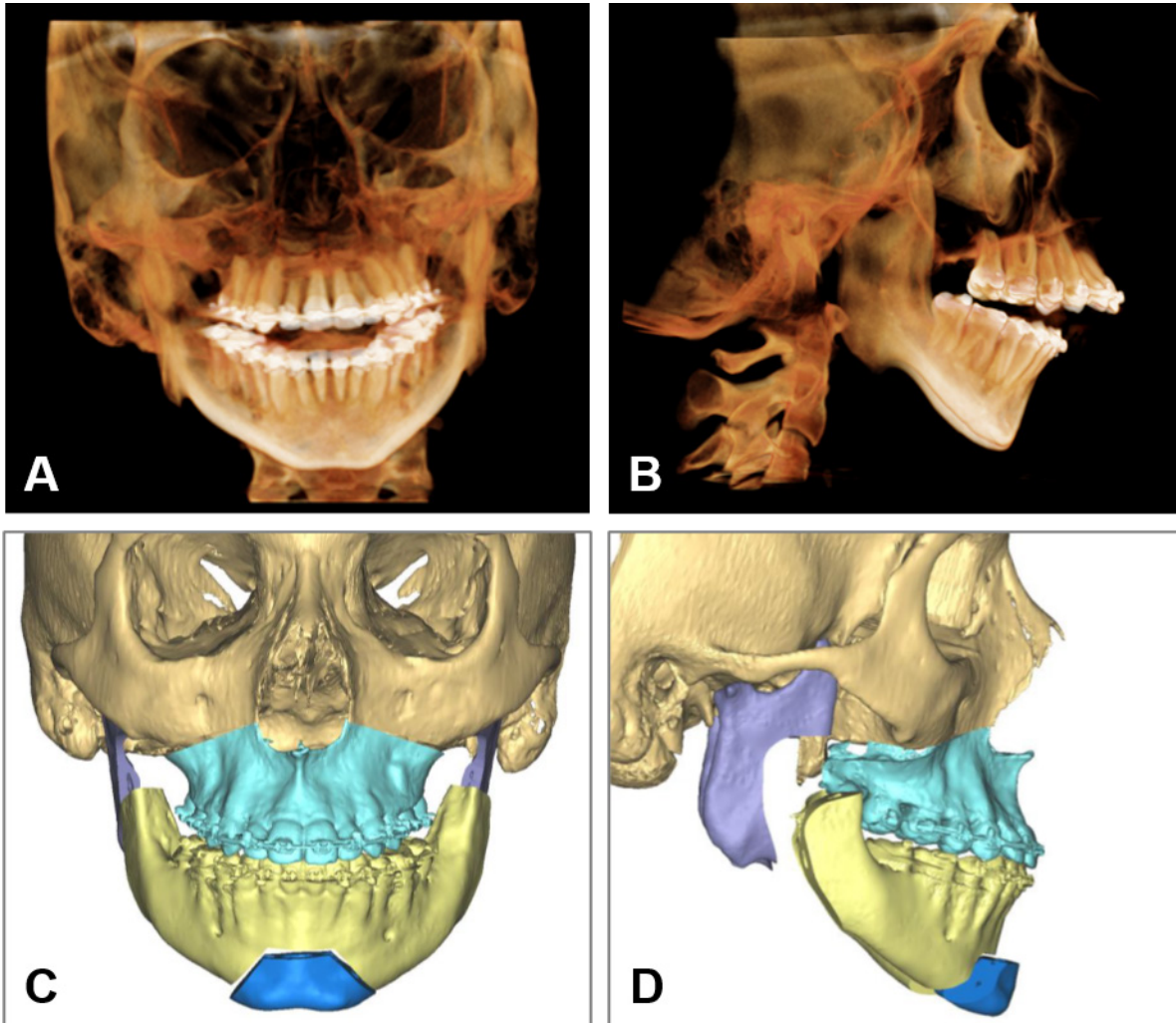


**Figure 4.**

Lateral view photographs of patient 2 taken preoperatively (A) and 2 months postoperatively (B). The preoperative image demonstrates significant Class II malocclusion and characteristics of severe mandibular hypoplasia. At 2 months postoperative, normal occlusion was restored, and the patient was extremely satisfied with the outcomes.

# Treatment of Severe Mandibular Hypoplasia using ViviGen Formable® Cellular Bone Matrix combined with Custom Intraoral Guides and Plates in Two Patients

CASE STUDY

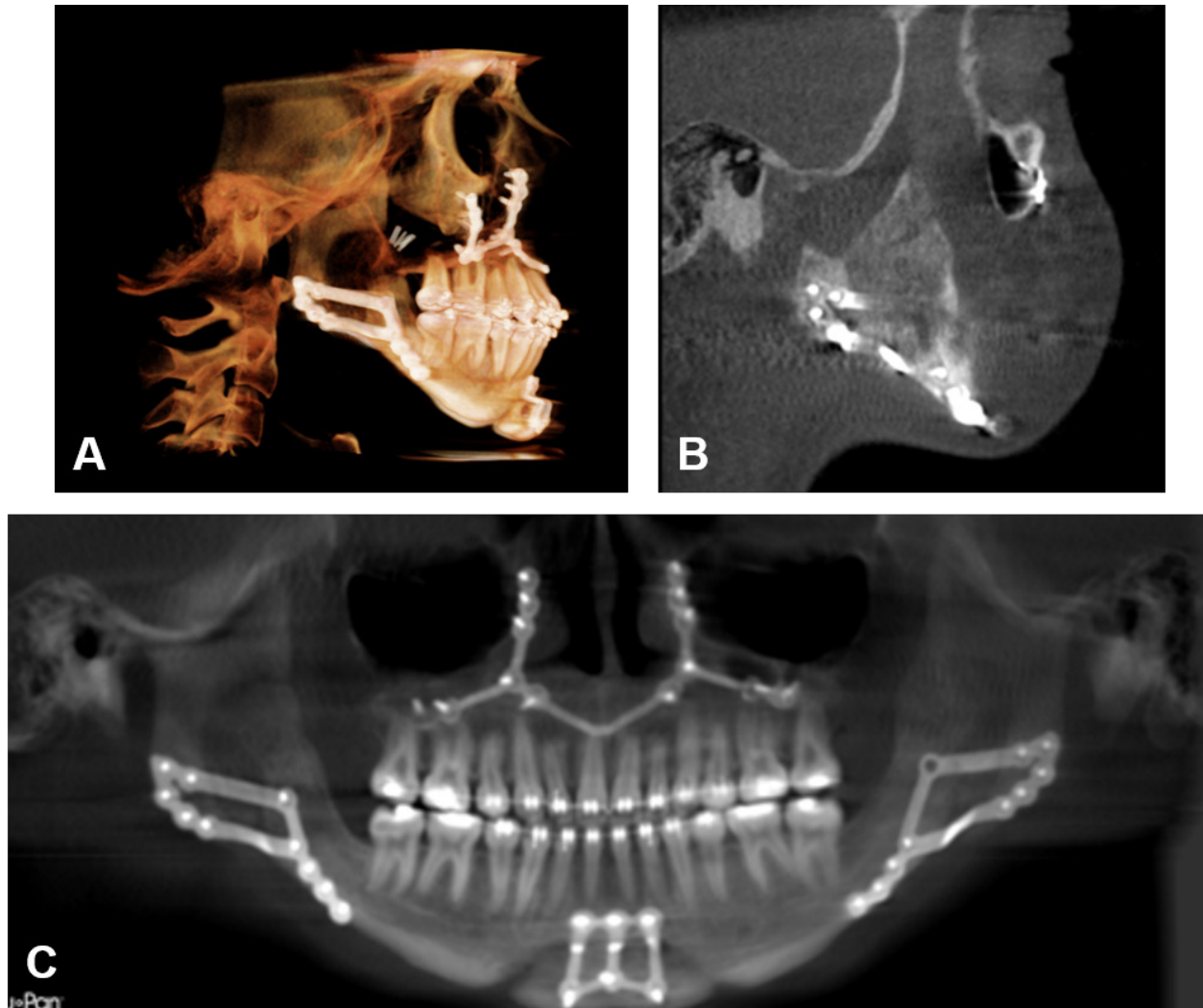


**Figure 5.**

CBCT images of patient 2 showing the anterior (A) and lateral (B) views demonstrate significant mandibular hypoplasia and a small posterior airway space. Three-dimensional reconstructed CBCT images from the presurgical plan showing the planned positional changes of the maxilla and mandible (C and D). The presurgical plan indicated an advancement of 4 mm and 19 mm for the maxilla and mandible, respectively.

# Treatment of Severe Mandibular Hypoplasia using ViviGen Formable® Cellular Bone Matrix combined with Custom Intraoral Guides and Plates in Two Patients

CASE STUDY



**Figure 6.**

Postoperative clinical images of patient 2 taken at 6 months. Lateral CBCT scan (A), CBCT section taken in the sagittal plane (B), and a reconstructed panoramic radiograph (C) demonstrate good integration of ViviGen Formable and progressed osseous healing at the osteotomy sites.

# Treatment of Severe Mandibular Hypoplasia using ViviGen Formable® Cellular Bone Matrix combined with Custom Intraoral Guides and Plates in Two Patients

CASE STUDY

## Conclusions

This report describes the successful treatment of severe mandibular deficiencies in two patients using ViviGen Formable in a complex bimaxillary surgical approach. The use of ViviGen Formable combined with the custom guides and plates reduced the operative time compared to traditional approaches.<sup>7</sup>

Results from case studies are not predictive of results in other cases. Results in other cases may vary. Please refer to the instructions for use for a complete list of indications, contraindications, warnings and precautions.

## References

1. Jenzer AC, Schlam, M. Retrognathia. StatPearls [Internet] 2019 Jan 2019 Mar 24 [cited 2019 10 Oct]; Available from: <https://www.ncbi.nlm.nih.gov/books/NBK538303/>.
2. Posnick JC and A Sami. Use of allogenic (iliac) corticocancellous graft for Le Fort I interpositional defects: technique and results. *J Oral Maxillofac Surg*, 2015. 73(1): 168 e1-12.
3. Alyahya A and GRJ Swennen. Bone grafting in orthognathic surgery: a systematic review. *Int J Oral Maxillofac Surg*, 2019. 48(3): 322-331.
4. Khan WS, Rayan F, Dhinsa BS, Marsh D. An osteoconductive, osteoinductive, and osteogenic tissue-engineered product for trauma and orthopaedic surgery: how far are we? *Stem Cells Int*. 2012;2012:236231.
5. Reichert JC, Quent VM, Noth U, Hutmacher DW. Ovine cortical osteoblasts outperform bone marrow cells in an ectopic bone assay. *J Tissue Eng Regen Med*. 2011;5(10):831-844.
6. Tortelli F, Tasso R, Loiacono F, Cancedda R. The development of tissue-engineered bone of different origin through endochondral and intramembranous ossification following the implantation of mesenchymal stem cells and osteoblasts in a murine model. *Biomaterials*. 2010;31(2):242-249.
7. Tsai CY, et al. Blood loss and operative time associated with orthognathic surgery utilizing a novel navigation system in cleft lip and palate patients. *J Formos Med Assoc*. 2019;118(2): 588-599.

LifeNet Health helps to save lives, restore health and give hope to thousands of patients each year. We are the world's most trusted provider of transplant solutions, from organ procurement to new innovations in bio-implant technologies and cellular therapies—a leader in the field of regenerative medicine, while always honoring the donors and healthcare professionals that allow the healing process.

## LifeNetHealth.org

LifeNet Health, the LifeNet Health logo, ViviGen, and ViviGen Formable are registered trademarks of LifeNet Health.

©2021 LifeNet Health, Virginia Beach, VA. All rights reserved.

68-20-325.00

©DePuy Synthes 2021. All rights reserved.

173105-210407 DSUS